

# About Scoliosis

## Symptoms, causes, treatment

### Information for patients and parents

---

#### WHAT IS SCOLIOSIS?

Scoliosis was originally a Greek word meaning curved or bent. Today it is a word used to describe the most common type of spinal curvature. Scoliosis is simply a descriptive term, like headache, and not a precise diagnosis.

When a scoliosis develops the spine bends sideways and rotates along its vertical axis. These changes have cosmetic and physiological effects with long-term consequences which may result in significant health problems with severe curves.

#### TYPES OF SCOLIOSIS

There are many causes of scoliosis, like there are many causes of headache. It is the doctor's task to determine which type of scoliosis the patient has.

#### IDIOPATHIC SCOLIOSIS

The word idiopathic also comes from the Greek language and means pathology unto itself. More simply, idiopathic means a condition not associated with any other disease or disorder. Unfortunately the term idiopathic is widely used in medical literature to indicate the cause of a given condition is unknown.

There are three main types of idiopathic scoliosis which are classified according to the age of onset.

**INFANTILE**– A curvature that develops before a child is two years old. Nine out of ten of these curves will spontaneously resolve. This type of scoliosis is very rare in Australia.

**JUVENILE**– A curve that develops in the age range of two to ten years. This type is also rare in this country.

**ADOLESCENT IDIOPATHIC SCOLIOSIS (AIS)** – This type appears in early adolescence and is much more common in girls than boys. While the incidence of very small curves is similar in both sexes, the ratio of boys to girls for curves in the treatment category is 1 : 8-10. AIS in girls accounts for about 90 percent of curves seen in clinical practice.

**CONGENITAL**– In this type a curve develops because of congenitally abnormal vertebrae. This form of curvature is often associated with congenital abnormalities in other body systems such as the heart and kidney. Detailed investigation of these children is required.

**NEUROMUSCULAR**– A wide variety of diseases and disorders of the central nervous system (brain), nerves and muscles can, but not invariably, result in the development of scoliosis. Muscular dystrophy is one such condition in which scoliosis can occur.

**PARALYTIC**– This is the term applied to the curvature which frequently develops when there is loss of spinal cord function early in life from disease or disorder, particularly injury (quadriplegia and paraplegia).

The management of the above-mentioned types of scoliosis is very much tailored to the individual patient and the underlying condition. There are many factors which enter into the decision-making process and the advice given to the patient and the family by the spinal surgeon.

\* \* \*

IN AS MUCH AS APPROXIMATELY 90 PERCENT OF THE PATIENTS SEEN IN SCOLIOSIS CLINICS ARE ADOLESCENT GIRLS WITH AIS THE REMAINDER OF THIS BROCHURE CONCERNS THIS DISORDER AND ITS MANAGEMENT. HOWEVER, THE MANAGEMENT OF CURVES OF OTHER AETIOLOGY IS GENERALLY ALONG THE SAME PRINCIPLES AS THOSE USED IN AIS.

## ADOLESCENT IDIOPATHIC SCOLIOSIS

### WHAT CAUSES AIS?

First, there are many myths about causation (aetiology).

- It is not a postural problem.
- You do not get scoliosis from a soft mattress.
- The carrying of heavy school bags neither causes a curve nor makes an existing one worse.
- You do not get scoliosis from watching too much television and eating too much junk food.
- Scoliosis is not contagious - you cannot catch it from someone who has a curvature.

A positive family history is a definite risk factor for AIS. Instead of being called idiopathic it would be more correct to say the vast majority of AIS patients have familial (genetic) scoliosis. But, traditions die hard in medicine. There is also sound scientific evidence that undefined 'environmental' factors play a role in causation. Hence, it is generally agreed by those who work in this field that the inheritance of AIS is what is termed multifactorial. The yet-to-be identified gene(s) have a very strong tendency to be passed down on the female side. However, there are no hard and fast rules for the pattern of inheritance and a girl or a boy who develops AIS may be the first one to do so in several generations of a family. Much research needs to be done to solve the problem that can be solved and will be solved in time.

If an adolescent is found to have AIS then it is a wise precaution and good medicine that his/her siblings be examined for the condition, but not before the 11<sup>th</sup> year. The most likely affected first degree relative is a maternal female cousin.

### THE OUTWARD SIGNS OF SCOLIOSIS

These depend in greater part on where the curve is located in the spine. The curve patterns are named according to the location of the most rotated vertebra(e) which is at the apex of the curve. There are three common single patterns - thoracic, thoracolumbar and lumbar. The second of these has its apex at the junction between the thoracic and lumbar regions. Curves may point in either direction but the right thoracic and left lumbar curves are the most common patterns. A double curve pattern is also common with right thoracic and left lumbar components. The neck (cervical) region is not affected by AIS.

Figure 1 shows the outward signs of AIS in an adolescent girl with a right thoracolumbar scoliosis. These signs, which are less obvious if a girl is overweight, tend to be more marked the higher in the spine is the location of the apex.

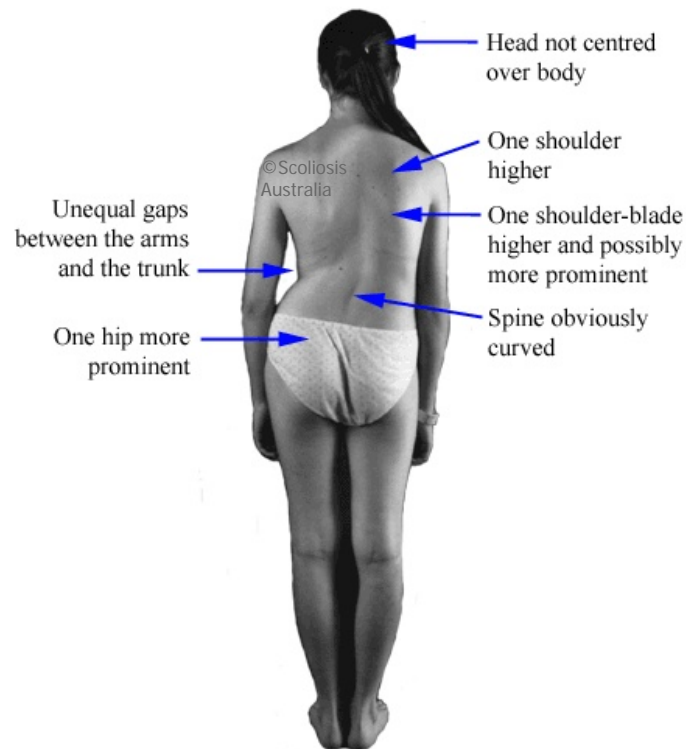


Figure 1.

## SCREENING FOR SCOLIOSIS

Where properly conducted school screening programs are carried out these should be supported and participation encouraged. School screening is best performed in girls in Years 7 and 9 (11 and 13 years of age). The Spine Society of Australia recommends that if screening is to be restricted on budgetary grounds, it should be limited to girls in Year 7. No case has ever been made for the routine screening of boys.

A two-tier screening process is recommended, the first being by school nurses trained in the **Forward Bend Test** (FBT - see below). Confirmation of a structural scoliosis by a doctor should take place before a family is notified. Over-diagnosis, a pitfall in screening programs, is best avoided by this two-tier approach. The notification rate should be less than three percent.

The abandonment of school screening programs led to the introduction of the National Self-Detection Program. This entails the distribution of a brochure to girls in Years 7 and 9 via the school systems. The thrust of this approach is to place responsibility for curve detection on the adolescent population and for management of minor curves on the family doctor. Over-referral to specialists is to be avoided. Most curves do not require active treatment.

## THE FORWARD BEND TEST

This is the key to the detection of scoliosis and it demonstrates the fixed rotatory component of a curve. In the thoracic region the ribs follow the rotating spine and move posteriorly and upwards, giving a prominence on the side of the apex - a right thoracic curve will have a right thoracic prominence in the FBT. In the lumbar region there are no ribs so with a lumbar curve the muscles on the side of the apex become more prominent. This is called the bolster sign because of the appearance of the prominence being similar to that of a long pillow (bolster). The prominence with thoracolumbar curves is a mixture of the above two described findings. Figure 2 demonstrates a correctly performed FBT in the girl shown in Figure 1.



**Figure 2**

## X-RAY EXAMINATION

This is required once a clinical diagnosis of all forms of scoliosis is made. Education programs for [family doctors](#) and [radiologists](#) have been developed to ensure that exposure to x-rays is kept to a minimum. The standard film required for the initial assessment is well within established safety limits.

## MANAGEMENT

First and foremost patients with AIS and their parents must understand that the diagnosis of AIS is a clinical and radiological one. The diagnosis is one of exclusion, that is the exclusion of those conditions such as neuromuscular disorder etc which can produce a curve. There are no biochemical or other markers (blood tests) specific for AIS. Further, there are no markers which will allow a spinal surgeon to predict accurately whether or not a given curve will progress. However, there are sound data on the probability (the risk) or progression as detailed in Table 1.

RISK OF PROGRESSION IN AIS			
Degree of curve Cobb angle	Age 10- 12	Age 13- 15	Age over 16
<20°	25%	10%	0%
20°-30°	60%	40%	10%
30°-60°	90%	70%	30%
>60°	100%	90%	70%
Data generated by the Scoliosis Research Society, Chicago, Illinois, USA			

It is readily deduced from this table that curves are most likely to progress and require active treatment (bracing or surgery) the larger the curve is at presentation and the age at which medical advice is first sought. This is because curves progress most rapidly during the growth spurt – 11-13 years in girls and about 18 months later in boys. These are average figures and averages only appear on paper. Early breast development in girls is a reliable sign of the onset of the spurt. The commencement of periods (menarche) is not reliable in this regard and the average age for this event is 13-15 years, by which time the spurt is over.

However, it is dangerous to apply rigid rules to biological events. Every girl and boy is different from all others.

The management of scoliosis centres on regular physical examination through the growth phase with x-rays as required. This is important because curve progression may take place without the patient being aware of any change. Fourth monthly visits are usual in the spurt phase and less frequently thereafter until growth has ceased and the patient is skeletally mature. Here again there are no hard and fast rules.

AIS patients soon become conversant with the 'angle' of their curves. This is called the Cobb angle and is measured on the x-ray. The only treatments which are effective in the management of AIS are bracing and surgery. The lay press abounds with claims for success with naturopathy, chiropractic manipulations, exercise programs (physiotherapy), electrical stimulation and so on. None of these supposed treatments can withstand critical analysis. The criterion for success of a given treatment is to produce accurate measurements of the Cobb angle before and after a treatment program and this the above-cited 'therapies' cannot do.

Minor curves <25 degrees do not require any treatment and observation only is indicated throughout the growth phase. No restrictions are placed on the young person's activities. Although scoliosis by definition (a curve of 10° or more) is present in one out of ten adolescent girls, **only two to three per thousand** come into the active treatment range. The surgery rate is approximately one per thousand.

## BRACE TREATMENT

Brace treatment aims to control a curve and contain it at an acceptable angle through the growth phase. It does not 'cure' scoliosis. External forces applied to the growing skeleton are very effective in modulating the shape of some structures. For example, orthodontic treatment. Here the braces are firmly attached to the teeth and moreover the young patient attends the orthodontist's surgery on a regular basis to have the braces tightened. A scoliosis brace does not have this decided mechanical advantage but in suitable candidates for a bracing program who are compliant with optimal brace wearing the success rate is in the order of 80 percent and so in these patients an operation is avoided.

There is no standard approach to bracing for AIS. However, there is widespread general agreement that in the skeletally immature patient bracing may be purposefully undertaken with some curves in the 30-40 degree range. It is also agreed that before bracing is instituted there must be an x-ray documented progression of at least five degrees. The reason for this restriction is that one-third of AIS curves more than 30 degrees do not progress if nothing is done. The reason for the stabilisation of such curves is unknown.

Every spinal surgeon has a somewhat different approach to bracing for scoliosis and this should be explained in depth to the patient and the parents when this option is being considered.

## SURGERY

The last twenty years have seen major advances in surgical techniques for the correction of spinal deformity from all causes. The basic principle is to apply some form of internal fixation to the spine and to correct the curve within the limits of safety. This may be carried out by one of many techniques but usually involves the application of stainless steel rods, hooks and screws to the spine in the corrected position and, most important, to join the vertebrae together by a spinal fusion with bone graft from the patient's pelvis. The indications for a particular technique is influenced by many factors. The spinal surgeon uses the method that works the best for him/her and should be explained in detail to the patient.

Surgery for AIS has been made very safe by the use of spinal cord monitoring during the operation. Here the electrical activity in the spinal cord is monitored at crucial stages of the operation to ensure it is not at risk. Nowadays, AIS patients give their own blood prior to operation so that they can be transfused with this if necessary.

Surgery for AIS produces excellent results and where indicated can be recommended with confidence. In the long-term the only restrictions that are placed on the average patient is for participation in body contact/collision/high impact sports.

The post-operative routine varies from surgeon to surgeon and this too should be discussed in detail well before operation.